

Department of Biology and Chemistry
Faculty Publications and Presentations

Liberty University

Year 1994

Chondroitin sulfate proteoglycans are a
common component of neuronal
inclusions and astrocytic reaction in
neurodegenerative diseases

David A. Dewitt* P. L. Richey† D. Praprotnik‡
J. Silver** G. Perry††

*Liberty University, dadewitt@liberty.edu

†

‡

**

††

This paper is posted at DigitalCommons@Liberty University.
http://digitalcommons.liberty.edu/bio_chem_fac_pubs/13

Short communication

Chondroitin sulfate proteoglycans are a common component of neuronal inclusions and astrocytic reaction in neurodegenerative diseases

D.A. DeWitt^{a,b,*}, P.L. Richey^b, D. Praprotnik^b, J. Silver^a, G. Perry^{a,b}

Department of ^aNeurosciences and ^bInstitute of Pathology, Case Western Reserve University, Cleveland, OH 44106, USA

Accepted 14 June 1994

Abstract

Previously, we showed three differentially sulfated forms of chondroitin sulfate proteoglycans (CSPG) associated with senile plaques, astrocytes and neurofibrillary tangles in Alzheimer's disease. Here, monoclonal antibodies were used to demonstrate CSPGs in other neurodegenerative diseases. CSPGs were found associated with inclusions of Parkinson's, diffuse Lewy body, Pick's diseases, and progressive supranuclear palsy. Reacting astrocytes in each of these neurodegenerative diseases and Huntington's disease showed immunoreactivity for CSPG. CSPG distribution in a variety of neurodegenerative diseases suggests that similar mechanisms may be involved in the accumulation of proteoglycans in a number of filamentous inclusions.

Key words: Alzheimer's disease; Astrocyte; Cytoskeleton; Extracellular matrix; Huntington's disease; Immunocytochemistry; Parkinson's disease

Several neurological conditions are characterized by intraneuronal, filamentous inclusions. The neuronal inclusions of Alzheimer's, Parkinson's, Pick's, diffuse Lewy body (DLB) diseases, and progressive supranuclear palsy (PSP), are principally composed of cytoskeletal components and share many common epitopes [6–10,18,20,22]. The clinical manifestations of the diseases, neuronal populations affected, and the morphology of each inclusion are distinct. It is not known whether similar, fundamental processes are involved in the formation of neuronal inclusions, or if different types of inclusions arise through separate mechanisms.

Certain proteoglycans have been associated with different diseases. Proteoglycans are highly anionic macromolecules that are usually found associated with the extracellular matrix [13–15,31] where they have been shown to play roles in cell adhesion and proliferation. Proteoglycans consist of a core protein with one or more glycosaminoglycan side chains typically attached to a serine residue. Proteoglycans vary in the

composition of the core protein, the number and type of glycosaminoglycan chains and sulfate content. Heparan sulfate proteoglycans (HSPG) are found in systemic amyloidoses [12] as well as in the senile plaques and neurofibrillary tangles (NFTs) of Alzheimer's disease and Down's syndrome [19,24,25,26]. Previously, we found HSPG by demonstrating heparinase-sensitive bFGF binding sites in the inclusions of several neurodegenerative diseases, including Pick's and Parkinson's diseases and PSP. However, diffuse Lewy bodies lacked bFGF-binding sites. [17]

Chondroitin sulfate proteoglycans (CSPGs) can inhibit neurite outgrowth in vivo and in vitro [2,27]. CSPGs accumulate at injury sites in the central nervous system [1,16,21]. During injury to the CNS, C-6S CSPG is associated with reacting astrocytes and is particularly inhibitory to neurite outgrowth [16]. Whether astrocytes produce a specific proteoglycan core protein during injury, or simply alter the usual sulfation pattern is unknown.

Since CSPGs containing all three sulfation states of chondroitin were shown to be associated with senile plaques and NFTs of Alzheimer's disease [5], it seemed likely, as in the case of HSPG, that CSPGs might also be present in inclusions of other neurodegenerative diseases. In this immunocytochemical study, we

* Corresponding author. Division of Neuropathology, Institute of Pathology, Case Western Reserve University, 2085 Adelbert, Cleveland, OH 44106, USA. Fax: (1) (216) 368-8964.

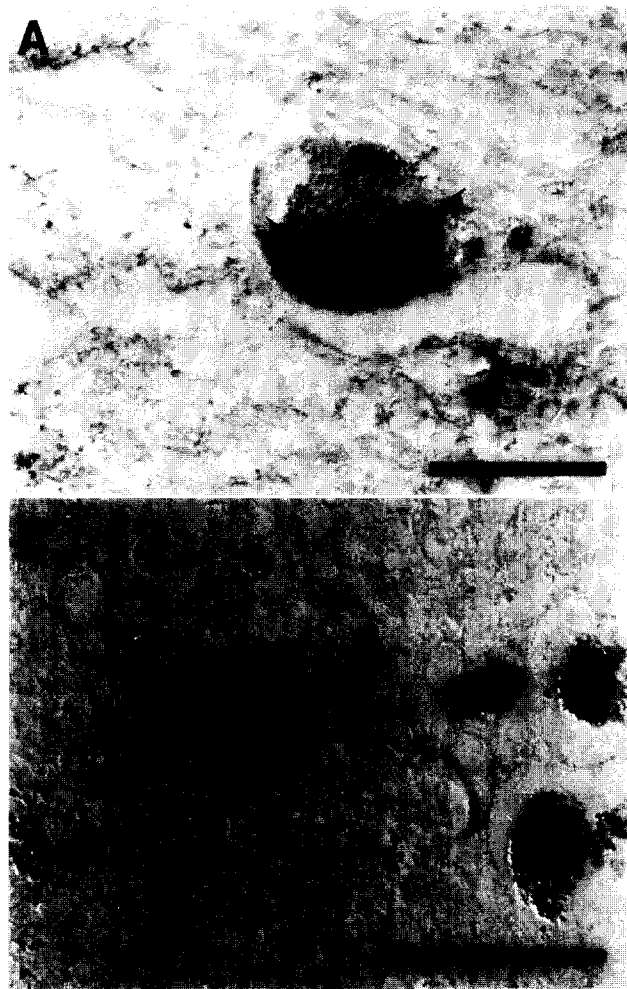

Fig. 1. Chondroitin sulfate immunoreactivity in Lewy bodies of Parkinson's disease. Substantia nigra neuron containing multiple Lewy bodies positive for (C-4S; panel A, arrowheads). Note typical rim-like staining. Lewy bodies were also seen with a homogeneous, pale staining (C-6S; panel B, arrowhead). Bar = 25 μ m.

demonstrate CSPG in a variety of inclusions and reacting astrocytes associated with neurodegenerative diseases. Our study suggests that the inclusion-related cytoskeletal changes may be part of a larger program of structural reorganization which includes proteoglycans.

Tissue sections from the brainstem of 5 cases of Parkinson's disease (ages 53–70) and from the frontal

or temporal cortex of 4 cases of DLB disease (ages 75–95) were examined for the presence of CSPG in Lewy bodies. In addition, the pons of 4 cases of PSP (ages 59–83), and frontal and temporal cortex of 2 cases of Pick's disease (ages 62, 68) were examined for the association of CSPG with these other neuronal inclusions. The caudate and putamen were examined from 2 cases of Huntington's chorea (ages 57, 61). Five control cases were also examined (57–83). All tissue was fixed in buffered formalin and embedded in paraffin prior to sectioning at 6 μ m.

Immunostaining was performed by the peroxidase anti-peroxidase method with 3'3'diaminobenzidine as the co-substrate [29]. To detect CSPGs, three monoclonal antibodies each raised to different sulfation states of chondroitin were used [4]. The three antibodies recognize the stubs of chondroitin 6-sulfate, chondroitin 4-sulfate, or unsulfated chondroitin, respectively, after chondroitinase digestion. Tissue sections were incubated with chondroitinase ABC [30] (Sigma) at 1 U/ml in Tris-acetate buffer (pH 8) for 2 h at 37°C or overnight at 20°C followed by overnight incubation at 4°C with antibody. Omission of the chondroitinase enzyme, substitution with heparinase and heparitinase [17] treatments, or omission of the primary antibody were used as controls. Antisera to τ or ubiquitin were used in adjacent sections to aid in identification of the inclusions. Antisera to glial fibrillary acidic protein (GFAP) was used to identify astrocytes.

The distribution of CSPGs in the different neurodegenerative diseases is summarized in Table 1. Lewy bodies of Parkinson's disease found in pigmented neurons of the substantia nigra were immunostained for unsulfated chondroitin (C-0S), chondroitin 4-sulfate (C-4S) and chondroitin 6-sulfate (C-6S). Most Lewy bodies had rim-like staining with less intense staining of the core (Fig. 1A). Some Lewy bodies were stained uniformly and appeared more pale (Fig. 1B).

Intraneuronal Pick bodies showed immunoreactivity for C-0S and C-6S, whereas C-4S immunoreactivity was confined to the cytoplasm surrounding Pick bodies (Fig. 2A). C-0S immunoreactivity was substantially weaker than C-6S and may indicate less of the unsulfated antigen.

Table 1

Chondroitin sulfate proteoglycans are found in the disease specific inclusions of a variety of neurodegenerative diseases

Disorder	Structure	C-0S	C-4S	C-6S
Alzheimer's disease	Senile plaques and NFTs	+	+	+
Progressive supranuclear palsy	NFTs	+	+	+
Pick's disease	Pick bodies	+	+	+
Parkinson's disease	Lewy bodies	+	+	+
Diffuse Lewy body disease	Lewy bodies	+	+	+

Unsulfated chondroitin (C-0S), chondroitin 4-sulfate proteoglycan (C-4S) and chondroitin 6-sulfate (C-6S) are found as indicated.

* The Pick body itself was unreactive for C-4, however, the cytoplasm surrounding the Pick body was positive. Chondroitin 4-sulfate is associated with but not in the Pick body.

Lewy bodies of DLB disease, which also have a cortical distribution, contained all three forms of chondroitin. These inclusions were identified as intracellular and juxtannuclear (Fig. 2B). The DLB disease inclusions had a reticular staining pattern. Interestingly, some DLBD inclusions were seen that lacked CSPG immunoreactivity, others were somewhat immunoreactive, while many were intensely immunoreactive. This pattern was the same for all three forms of CSPG.

Progressive supranuclear palsy was also examined. NFTs of PSP also contained C-0S, C-4S, and C-6S. Many large neurons contained CSPG apparently associated with fibrils inside the cell (Fig. 2C). C-0S immunoreactivity was substantially weaker than C-4S and C-6S, which may indicate fewer unsulfated glycosaminoglycan chains per proteoglycan core protein.

Astrocytic reaction could be found in each of the cases examined. These astrocytes showed C-4S and C-6S immunoreactivity. Of the cases examined, the Pick's cases showed the most extensive gliosis, as confirmed with antisera to GFAP. The Pick's cases also had the most intense and greatest number of CSPG-positive astrocytes (Fig. 3A). The cases of DLB disease had the least number of CSPG-positive, reacting astrocytes. In Parkinson's disease and PSP (Fig. 3B) the CSPG-positive astrocytes were seen among inclusion-bearing neurons. In the caudate and putamen of Huntington's disease, astrocytes positive for CSPG immunoreactivity were found (Fig. 3C) while the cortex of

these cases showed relatively few. In controls, only a small number of GFAP-positive astrocytes displayed CSPG immunoreactivity.

In all cases, chondroitinase digestion was required for antibody binding [4,5]. Antibody specificity was demonstrated by a lack of immunoreactivity following heparinase and heparitinase digestion or if chondroitinase treatment was absent.

In this study we demonstrated CSPGs associated with intraneuronal inclusions of several neurodegenerative diseases. Inclusions of Pick's, DLB, and Parkinson's diseases, and from PSP are associated with all three sulfation states of chondroitin. In addition, astrocytes contain C-4S and C-6S in these diseases as well as Huntington's disease. Huntington's disease cases were examined because this disease is characterized by astrogliosis and neuronal loss but a lack of inclusions.

In a previous study, we demonstrated that glial cells accumulate and secrete CSPGs in response to $A\beta$ as a substrate [3]. In this study, we found CSPG associated with astrocytes in neurodegenerative diseases not characterized by $A\beta$ deposits. Therefore, while $A\beta$ may play a key role in CSPG deposition around senile plaques in Alzheimer's disease, it is unlikely to be the sole initiator for CSPG accumulation in neurodegenerative diseases.

Extracellular proteoglycans have been shown to play roles in cell proliferation, migration, and cell adhesion. HSPGs and CSPGs are found primarily in the extracel-

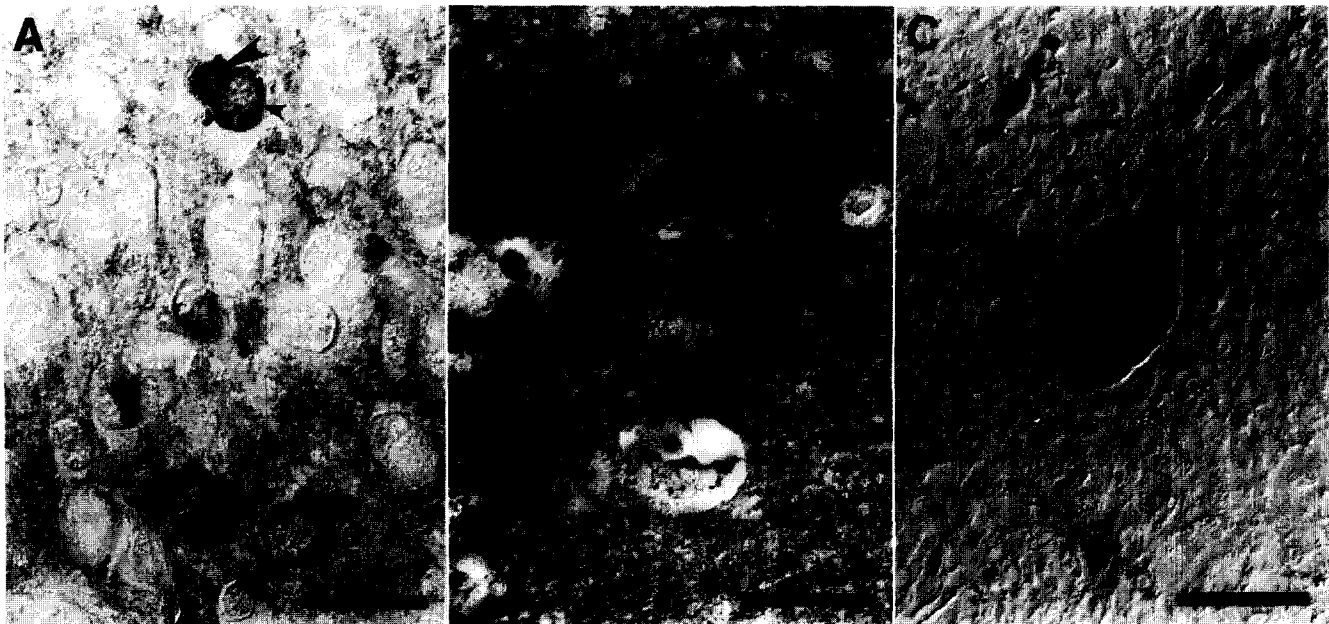

Fig. 2. Pick bodies usually showed weak immunoreactivity for chondroitin (arrowheads), however, the cytoplasm surrounding the Pick body was more intensely stained (C-4S; panel A, small arrowheads). Chondroitin immunoreactivity in diffuse Lewy bodies had a reticular staining pattern (C-4S; panel B, arrowhead). NFTs in progressive supranuclear palsy showed chondroitin immunoreactivity associated with fibrils within the cytoplasm (C-6S; panel C, arrowhead). Bar = 25 μ m.




Fig. 3. Reacting astrocytes show CSPG immunoreactivity. Astrocytes in gliosis of Pick's disease (C-6S; panel A). Some reactive astrocytes are seen in close proximity to neurons with inclusions. An astrocyte (small arrow) is located next to a PSP NFT (C-6S; panel B, large arrow). Astrocytes in the caudate of a Huntington's patient (C-6S; panel C). Bar = 20 μ m.

lular matrix, but have been found intracellularly [15,19,28]. HSPG and now CSPG have been shown to be a common component of neuronal inclusions. Ex-

cessive internal accumulation of proteoglycans could hinder normal intracellular transport, potentially inducing accumulation of many other proteins.

Proteoglycans may play an active role in the formation of these inclusions. Since the inclusions are comprised cytoskeletal components, one possibility is that the cytoskeletal proteins are interacting with the proteoglycans to form the inclusion. These inclusions are resistant to proteases. Proteoglycans have been shown to alter normal proteolytic degradation of proteins such as bFGF [23] and $A\beta$ [11]. In addition, systemic amyloidoses, which contain proteoglycans, are resistant to proteolysis. The accumulation of proteoglycans in the presence of abnormal cytoskeletal components could prevent the efficient degradation and removal of those abnormal fibrils, allowing them to persist. While different types of inclusions occur in distinct neuronal populations and consist of various proteins, proteoglycans appear to be a common component. Proteoglycan protection from proteolysis could be a fundamental mechanism leading to inclusion formation.

This work was supported by AG 07552 and AG 09287.

- [1] Bovolenta, P., Wandosell, F. and Nieto-Sampedro, M., Characterization of neurite outgrowth inhibitor expressed after CNS injury, *Eur. J. Neurosci.*, 5 (1993) 454–465.
- [2] Brittis, P.A., Canning, D.R. and Silver, J., Chondroitin sulfate as a regulator of neuronal patterning in the retina, *Science*, 255 (1992) 733–736.
- [3] Canning, D.R., McKeon, R.J., DeWitt, D.A., Perry, G., Wujek, J., Fredrickson, R. and Silver, J., β -Amyloid of Alzheimer's disease induces reactive gliosis that inhibits axonal outgrowth, *Exp. Neurol.*, 124 (1993) 289–298.
- [4] Couchman, J.R., Caterson, B., Christner, J.E. and Baker, J.R., Mapping by monoclonal antibody detection of glycosaminoglycans in connective tissues, *Nature*, 307 (1984) 650–652.
- [5] DeWitt, D.A., Silver, J., Canning, D.R. and Perry, G., Chondroitin sulfate proteoglycans are associated with the lesions of Alzheimer's disease, *Exp. Neurol.*, 121 (1993) 149–152.
- [6] Galloway, P.G., Bergeron, C. and Perry, G., The presence of tau distinguishes Lewy bodies of diffuse Lewy body disease from those of idiopathic Parkinson disease, *Neurosci. Lett.*, 100 (1989) 6–10.
- [7] Galloway, P.G., Mulvihill, P. and Perry, G., Filaments of Lewy bodies contain insoluble cytoskeletal elements, *Am. J. Pathol.*, 140 (1992) 809–822.
- [8] Galloway, P.G., Mulvihill, P., Siedlak, S., Mijares, M., Kawai, M., Padget, H., Kim, R. and Perry G., Immunochemical demonstration of tropomyosin in the neurofibrillary pathology of Alzheimer's disease, *Am. J. Pathol.*, 137 (1990) 291–300.
- [9] Galloway, P.G. and Perry, G., Tropomyosin distinguishes Lewy bodies of Parkinson disease from other neurofibrillary pathology, *Brain Res.*, 541 (1991) 347–349.
- [10] Gheuens, J., Cras, P., Perry, G., Boons, J., Ceuterick-de Groote, C., Lubke, U., Mercken, M., Tabaton, M., Gambetti, P., Vandermeeren, M., Mulvihill, P., Siedlak, S., Van Heuverswijn, H. and Martin, J.J., Demonstration of a novel neurofilament associated antigen with the neurofibrillary pathology of Alzheimer and related diseases, *Brain Res.* 558 (1991) 43–52.
- [11] Gupta-Bansal, R., Ziehler, W. and Wujek, J.R., Brunden, K.R., Potential role of proteoglycans in the accumulation and persis-

- tance of β -amyloid (A β) in Alzheimer's disease senile plaques, *Soc. Neurosci. Abstr.*, 19 (1993) 1471.
- [12] Kisilevsky, R. and Snow, A., The potential significance of sulfated glycosaminoglycans as a common constituent of all amyloids: or, perhaps amyloid is not a misnomer, *Med. Hypotheses*, 26 (1988) 231–236.
- [13] Kresse, H., Hausser, H. and Schönherr, E., Small proteoglycans, *Experientia*, 49 (1993) 403–416.
- [14] Margolis, R.K. and Margolis, R.U., Nervous tissue proteoglycans, *Experientia*, 49 (1993) 429–446.
- [15] Margolis, R.U., Aquino, D.A., Klinger, M.M., Ripellino, J.A. and Margolis, R.K., Structure and localization of nervous tissue proteoglycans, *Ann. NY Acad. Sci.*, 481 (1986) 46–54.
- [16] McKeon, R.J., Schreiber, R.C., Rudge, J.S. and Silver, J., Reduction of neurite outgrowth in a model of glial scarring following CNS injury is correlated with the expression of inhibitory molecules on reactive astrocytes, *J. Neurosci.*, 11 (1991) 3398–3411.
- [17] Perry, G., Richey, P., Siedlak, S.L., Galloway, P., Kawai, M. and Cras, P., Basic fibroblast growth factor binds to filamentous inclusions of neurodegenerative diseases, *Brain Res.*, 579 (1992) 350–352.
- [18] Perry, G., Rizzuto, N., Autilio-Gambetti, L. and Gambetti, P., Paired helical filaments from Alzheimer disease patients contain cytoskeletal components, *Proc. Natl. Acad. Sci. USA*, 82 (1985) 3916–3920.
- [19] Perry, G., Siedlak, S.L., Richey, P., Kawai, M., Cras, P., Kalaria, R.N., Galloway, P.G., Scardina, J.M., Cordell, B., Greenberg, B.D., Ledbetter, S.R. and Gambetti, P., Association of heparan sulfate proteoglycan with the neurofibrillary tangles of Alzheimer's disease, *J. Neurosci.*, 11 (1991) 3679–3683.
- [20] Perry, G., Friedman, R., Kang, D.H., Manetto, V., Autilio-Gambetti, L. and Gambetti, P., Antibodies to the neuronal cytoskeleton are elicited by Alzheimer paired helical filament fraction, *Brain Res.*, 420 (1987) 233–242.
- [21] Pindzola, R.R., Doller, C. and Silver, J., Putative inhibitory extracellular matrix molecules at the dorsal root entry zone of the spinal cord during development and after root and sciatic nerve lesions, *Dev. Biol.*, 156 (1993) 34–48.
- [22] Pollanen, M.S., Bergeron, C. and Weyer, L., Deposition of detergent-resistant neurofilaments into Lewy body fibrils, *Brain Res.*, 603 (1993) 121–124.
- [23] Saksela, O., Moscatelli, D., Sommer, A. and Rifken, D.B., Endothelial cell-derived heparan sulfate binds basic fibroblast growth factor and protects it from proteolytic degradation, *J. Cell Biol.*, (1988) 743–751.
- [24] Siedlak, S.L., Cras, P., Kawai, M., Richey, P. and Perry, G., Basic fibroblast growth factor binding is a marker for extracellular neurofibrillary tangles in Alzheimer disease, *J. Histochem. Cytochem.*, 39 (1991) 899–904.
- [25] Snow, A.D., Mar, H., Nochlin, D., Sekiguchi, R.T., Kimata, K., Koike, Y. and Wight, T.N., Early accumulation of heparan sulfate in neurons and in the beta-amyloid protein-containing lesions of Alzheimer's Disease and Down's Syndrome, *Am. J. Pathol.*, 137 (1990) 1253–1270.
- [26] Snow, A.D., Willmer, J.P. and Kisilevsky, R., Sulfated glycosaminoglycans in Alzheimer's disease, *Human Pathol.*, 18 (1987) 506–510.
- [27] Snow, D.M., Lemmon, V., Carrino, D.A., Caplan, A.I. and Silver, J., Sulfated proteoglycans in astroglial barriers inhibit neurite outgrowth in vitro, *Exp. Neurol.*, 109 (1990) 111–130.
- [28] Su, J.H., Cummings, B.J. and Cotman, C.W., Localization of heparan sulfate glycosaminoglycan and proteoglycan core protein in aged brain and Alzheimer's disease, *Neuroscience*, 51 (1992) 801–813.
- [29] Sternberger, L.A., *Immunocytochemistry*, 3rd edn., Wiley, New York, 1986.
- [30] Yamagata, T., Saito, H., Habuchi, O. and Suzuki, S., Purification and properties of bacterial chondroitinases and chondrosulfatases, *J. Biol. Chem.*, 243 (1968) 1523–1535.
- [31] Yanagishita, M., Function of proteoglycans in the extracellular matrix, *Acta Pathol. Japon.* 43 (1993) 283–293.